

BUNA
DIMINEATA



VERTIJ, AMEȚEALĂ, EXPLORĂRI ORL
Clinica NOVA

MANIFESTARI ORL IN PANDEMIA SARS COV 2

DR IOANA VODA - MD, PHD

ORL OTO- NEUROLOGIE

CLINICA NOVA EXPLORARI ORL

BUCURESTI SI CLUJ



VERTIJ, AMEȚEALĂ, EXPLORĂRI ORL

Clinica NOVA

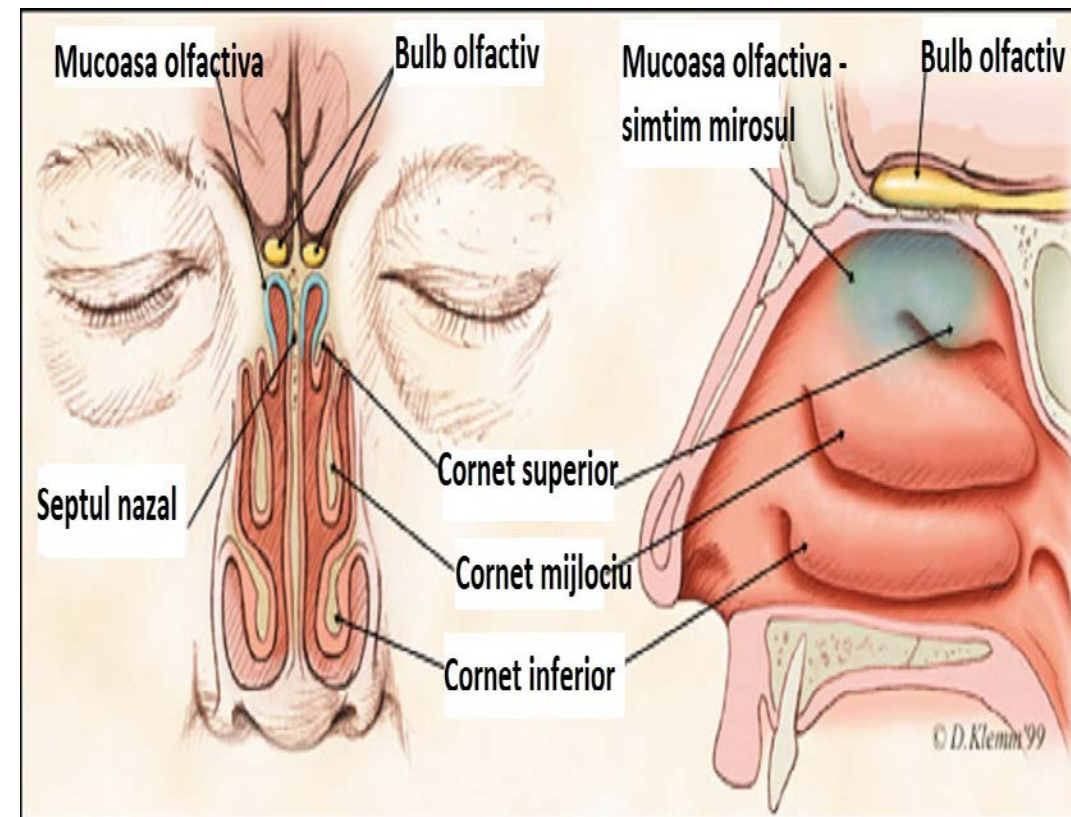
MANIFESTARI NAZALE -

SIMPTOME

- 1. NAS USCAT
- 2. PARESTEZII/ USTURIMI
- 3 SECRETII - RINOREE APOASA MODERATA, FRECVENT POSTERIOARA
- 4 FOARTE RAR - OBSTRUCTIE NAZALA
- 5. ANOSMIE - TEMPORARA/ ANOSMIE PRELUNGITA

MECANISME FIZIOPATOLOGICE:

- 1. AGENTUL PATOGEN - VIRUSUL – 2 TELURI - SA SUPRAVIETUIASCA SI SA SE PROPAGE - SE ADAPTEAZA SI FACE MUTATII
- 2. GAZDA – GENETIC, IMUNITATE - IMU/ IMC/ VARSTA/ COMORBIDITATI SI MAI ALES FACTORI LOCALI - SINDROAME OBSTRUCTIVE NAZALE - POLIPOZE NAZALE CRONICE, ADENOIDITE -



CE ATITUDINE?

FATA DE VIRUS

- SCADEREA CANTITATII VIRUSULUI
- INHALARE SCAZUTA - CAMERE AERISITE, EVITARE AGLOMERATII - CUMPARATURI LA PRIMELE ORE - MAGAZINE GOALE, MASCA
- SPALATURI NAZALE
- VIRUCIDE LOCALE



FATA DE GAZDA

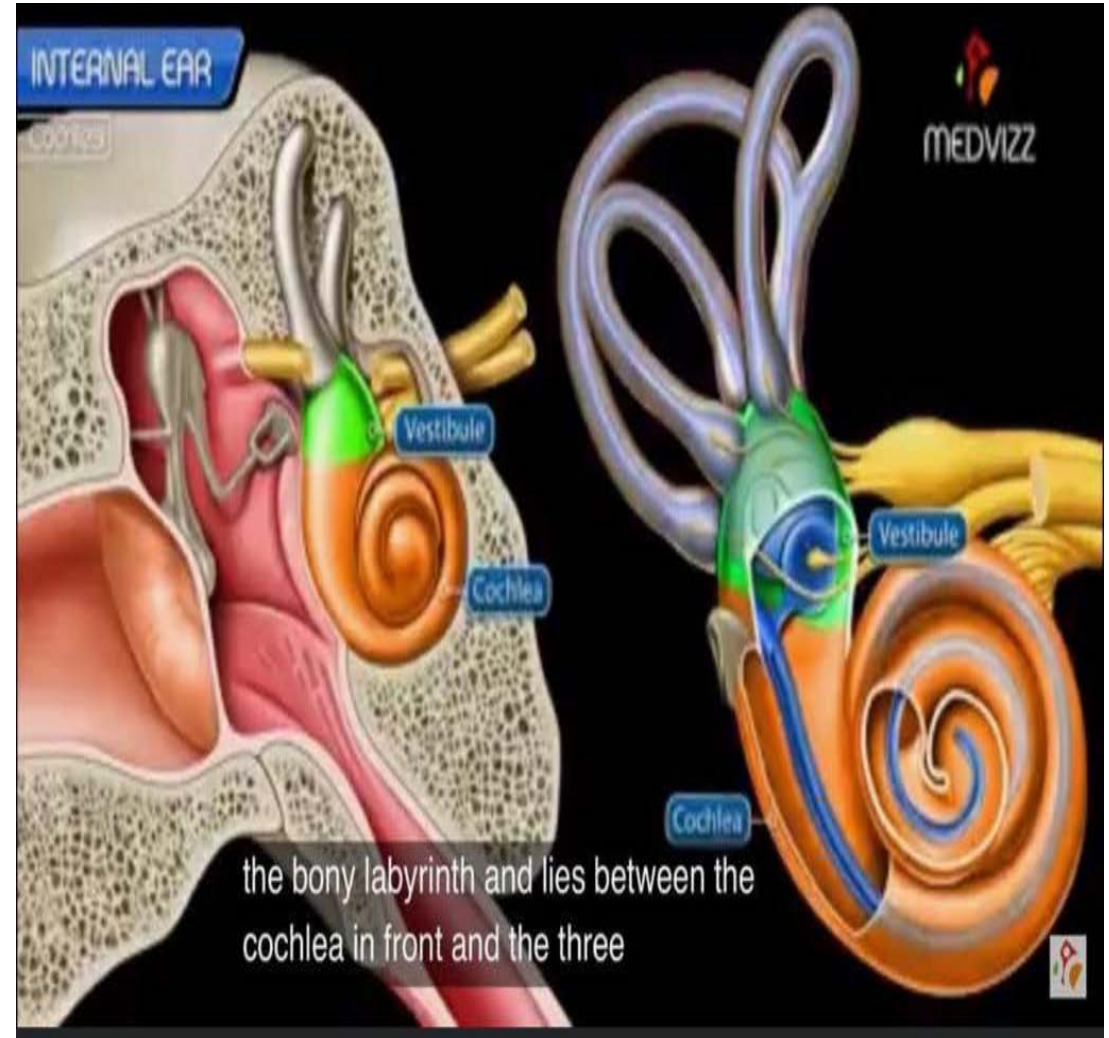
- CURATIREA MUCOASEI NAZALE
- STIMULARE SECRETII, PENTRU ELIMINARE - INHALATII A LA BUNICA
- SIMPTOMATICE NAZALE - IN FUNCTIE DE TIPUL AFECTARII PACIENTULUI
 - SIMPTOMATICELE - NU SE POT DA MAI MULT DE 7-10 ZILE
 - TRATAMENT PENTRU NEUROPATIE SENZORIALA – AFECTARE BUTONI TERMINALI – RECEPTORII OLFACTIVI/ NERVUL/ EDEMUL MUCOASEI NAZALE
 - REEDUCAREA OLFACTIEI (NU UITATI DE MIROSURILE TARI, IUTI, IRRITANTE = STIMULARE V)

MANIFESTARI FARINGIENE

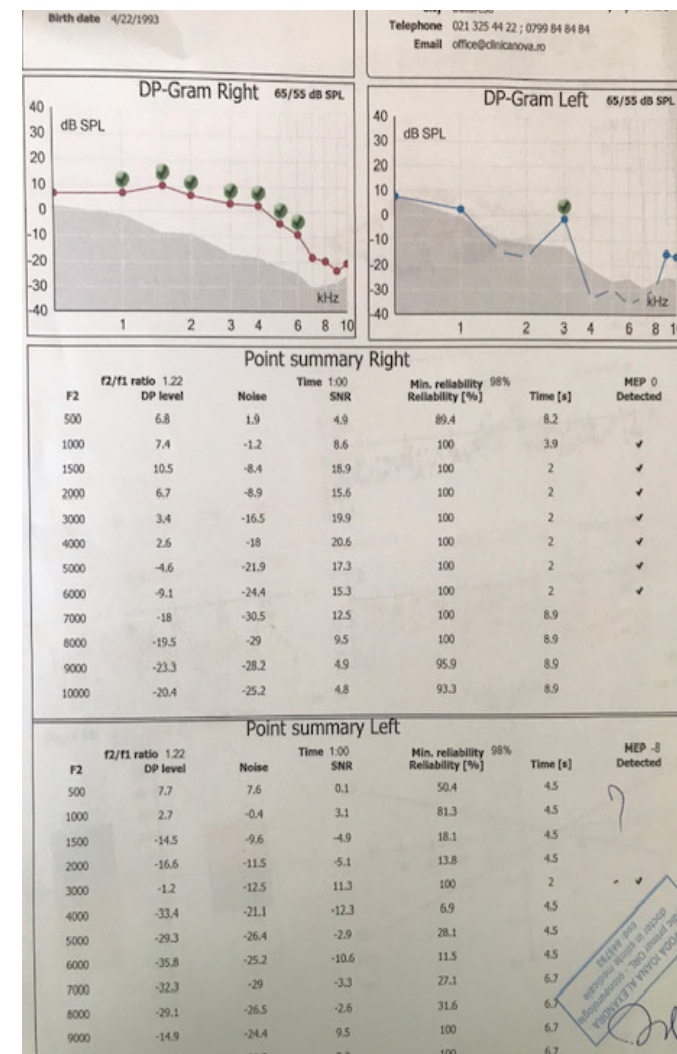
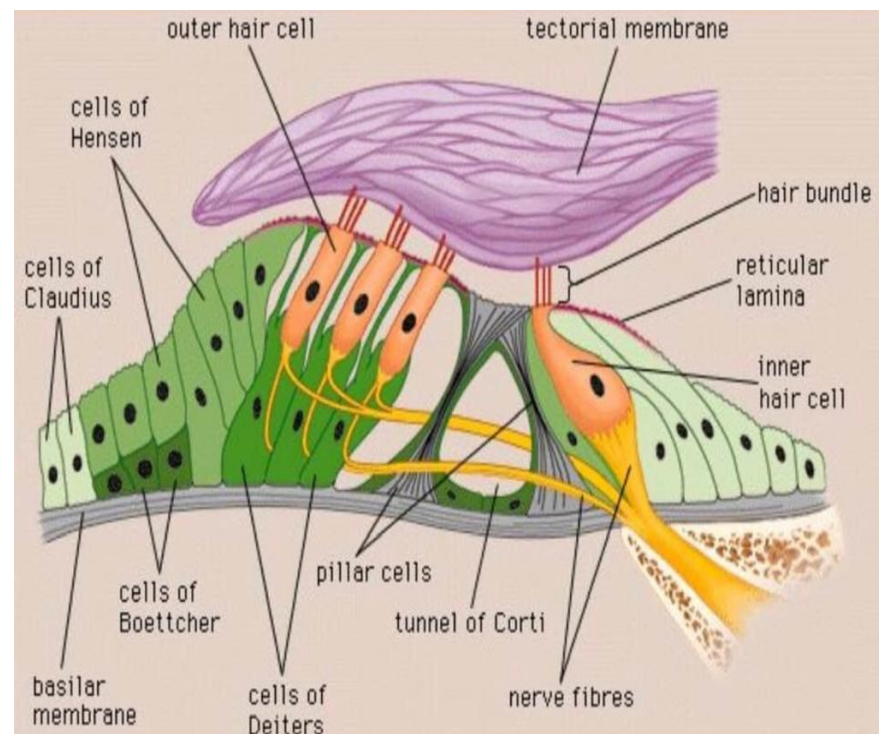
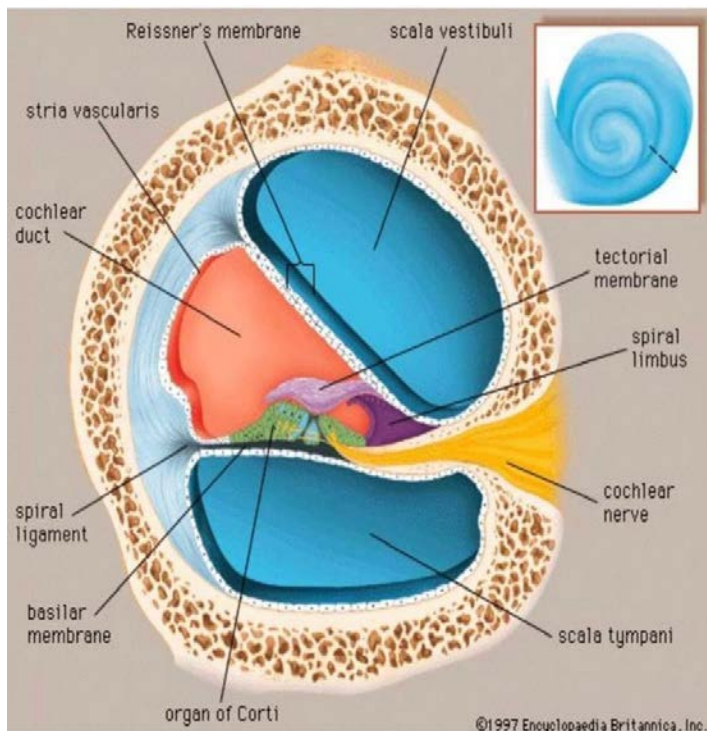
- RARE – FARINGITA DE PASAJ
- ACELASI TIP DE MUCOASA, CU ACEEASI STRUCTURA, IMUNITATE
- GAT USCAT, IRITAT
- FARA PUSTULE, FARA CONGESTIE MAJORA
- NU AMIGDALITA, NU GLOSITA

MANIFESTARILE OTICE

- DE URECHE EXTERNA –NU EXISTA
- DE URECHE MEDIE – OTITE MEDII/ SEROASE – SUNT DESCRISE IN LITERATURA - - NOI NU AM GASIT – CI DOAR USOARA CONGESTIE- AINS ORALE, CALDURA LOCALA, FARA APA
- DE URECHE INTERNA – POT FI: COHLEARE SI VESTIBULARE



PATOLOGIE COHLEARA - CELULE CILIAE EXTERNE COHLEARE/ NERV ACUSTIC/ HIDROPS ENDOLIMFATIC



MANIFESTARI AUDITIVE

TINITUS/ ACUFENE/ ZGOMOT IN URECHE – UNIC/ MULTIPLU – FRECVENTE DIFERITE, INTENSITATI DIFERITE

- UNI/ BILATERAL/ IN CAP
- FLUCTUANT/ CONSTANT,
- MASCABIL/ SAU NU DE ZGOMOTUL DE FOND
- +/- INSOMNII +/- IRASCIBILITATE +/- APROSEXIE +/- CEFALIE

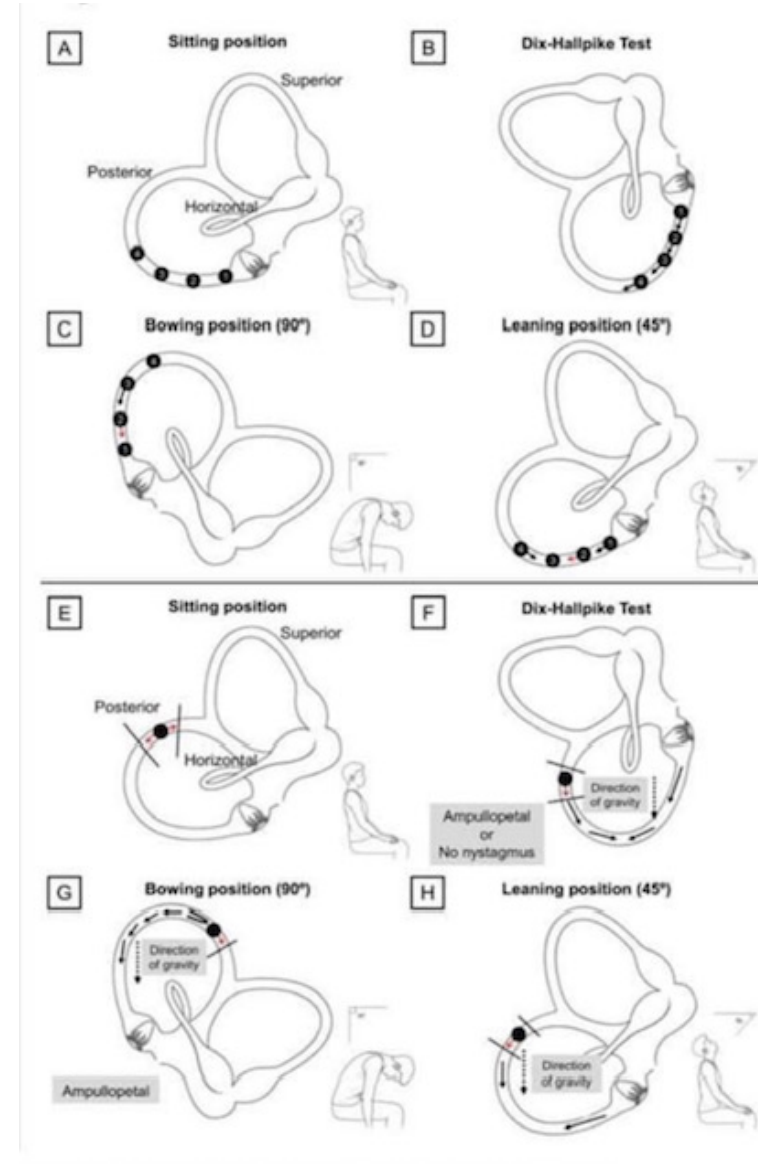
- HIPOACUZIE NEUROSENZORIALA UNILATERALA – TIP SURDITATE BRUSC INSTALATA/ HIPOACUZIE BRUSC INSTALATA (PLENITUDINE AURICULARA – URGENTA MAJORA – NEUROPATIE INFLAMATORIE / VASCULARA

MANIFESTARI VESTIBULARE

- VERTIJUL – FOARTE FRECVENT – VPPB – 30 % CRIZE SCURTE, REPETITIVE
- NEURONITA VESTIBULARA - 10 %- VASCULARA/ INFLAMATORIE – CRIZA UNICA , LUNGA, CU GREATA, VOMA, INSTABILITATE SI NY FIXABIL – ASIMETRIE MAJORA PERSISTENTA – 1-2 SAPT
- MIGRENA VESTIBULARA – 10 % CU/ FARA CEFALIE – MEC ISCHEMIC, ASIMETRIE MICA, FLUCTUANTA
- HIDROPS ENDOLIMFATIC/ BOALA MENIERE – 3 % - HIPOACUZIE ACUFENA SI URECHE INFUNDATA, DEZECHILIBRU
- PPPD – PERCEPTUAL PERSISTENT PHOBIC DIZZINESS – 2%
- AVC CEREBEL/ TRUNCHI CEREBRAL – IRM+ NEUROLOGIE – INSTABILITATE MAJORA, DEBUT SUPRA ACUT

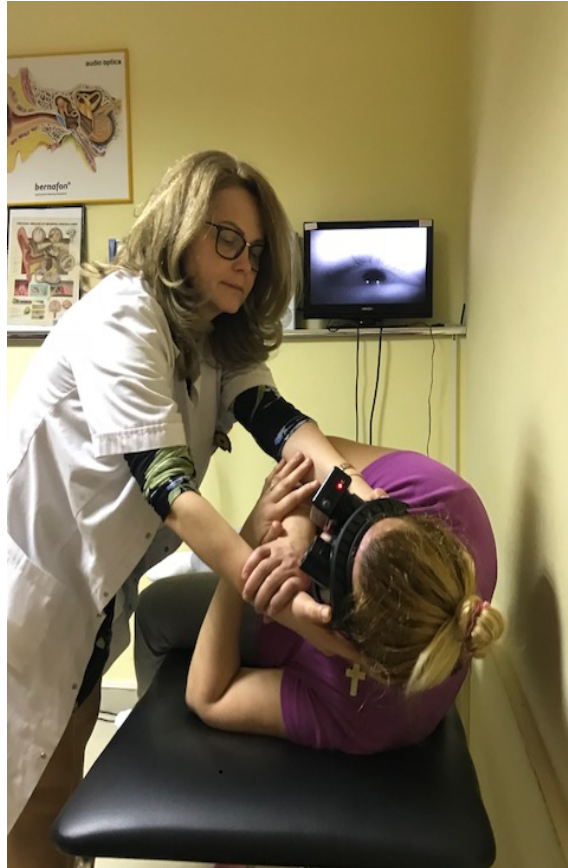
MANEVRE MULTIPLE DE REPOZITIE

- EPLEY
- SEMONT
- LEMPERT
- GUFONI
- YACOVINO
- ZUMA
- COMBINATII
- REPOZITII MECANICE CU TRV





MANEVRE DE DIAGNOSTIC – MANUALE SAU MECANICE

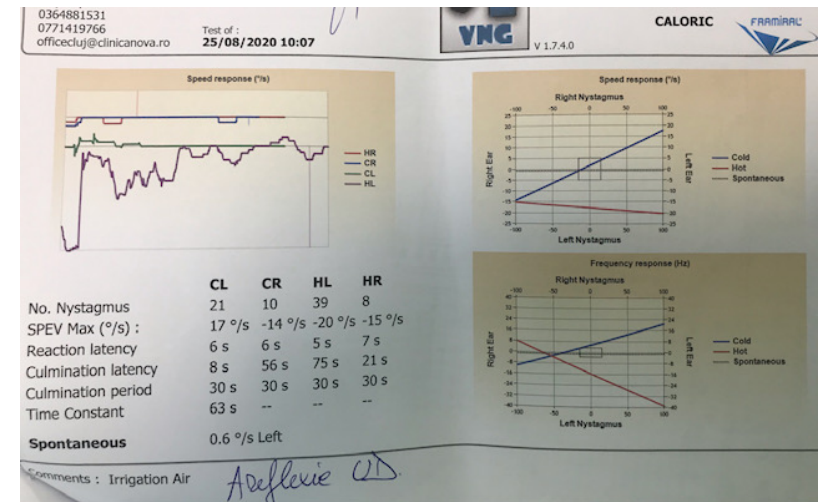
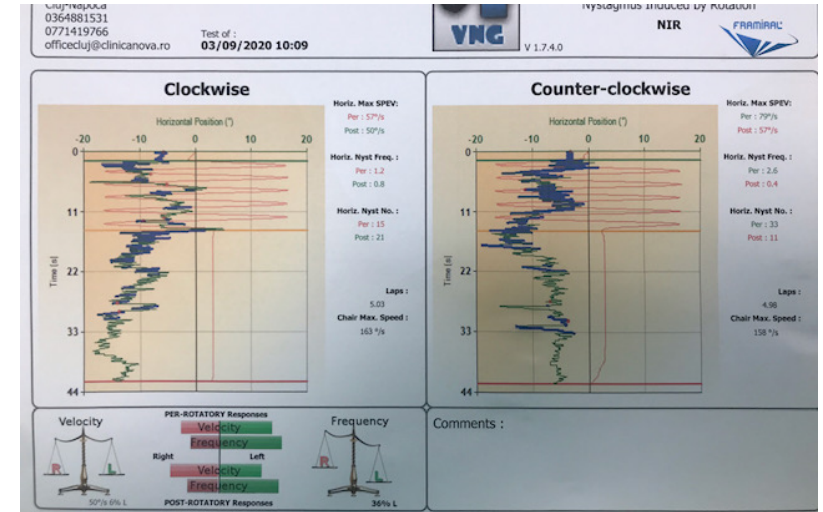
NECESITA OCHELARI DE VIDEONISTAGMOSCOPIE PENTRU A VEDEA DIRECTIA, SENSUL SI AMPLITUDINEA NISTAGMUSULUI



REPOZITIE MECANICA PE TRV – PENTRU CEI SUPRAPONDERALI, CU PATOLOGII CERVICALE-IVB,
HERNII CERVICALE, INTERVENTII CEREBRALE, PT RECIDIVE, PACIENTI RIGIZI, ANXIOSI, MULTICANAL



NISTAGMUS STANG – PERSISTENT, INDIFERENT DE POZITIE



MII DE MULTUMIRI – RAMANETI/ TINETI – VA SANATOSI

BIBLIOGRAFIE

1. Mao L, Jin H, Wang M, et al. Neurologic manifestations of hospitalized patients with coronavirus disease 2019 in Wuhan, China. *JAMA Neurol.* 2020;77(6):1–9
2. Baig A, Khaleeq A, Ali U, et al. Evidence of the COVID-19 virus targeting the CNS: tissue distribution, host-virus interaction and proposed neurotropic mechanisms. *ACS Neurosci.* 2020;11(7):995–998.
3. Wu Y, Xu X, Chen Z, et al. Nervous system involvement after infection with COVID-19 and other coronaviruses. *Brain Behav Immun.* 2020;97;18–22

CLINICA NOVA
EXPLORARI
ORL

BUCURESTI SI
CLUJ

VA
MULTUMESTE
PENTRU

INCREDERE SI
IMPREUNA
TREBUIE

SA REUSIM



VERTIJ, AMEȚEALĂ, EXPLORĂRI ORL

Clinica NOVA